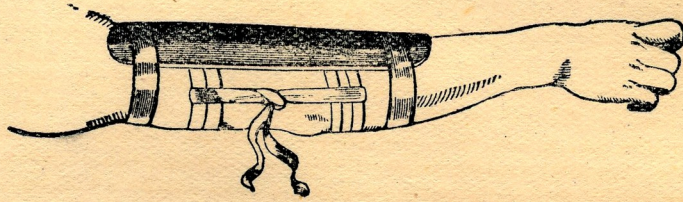
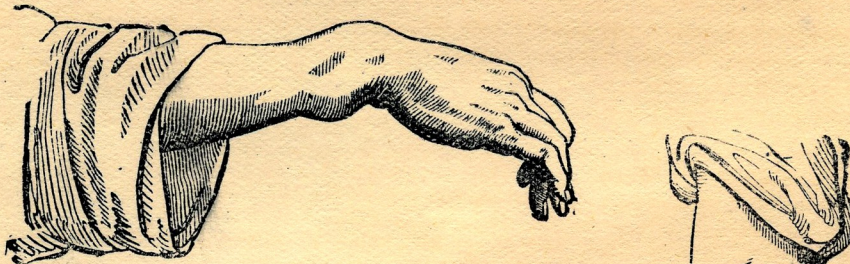


FRACTURES.



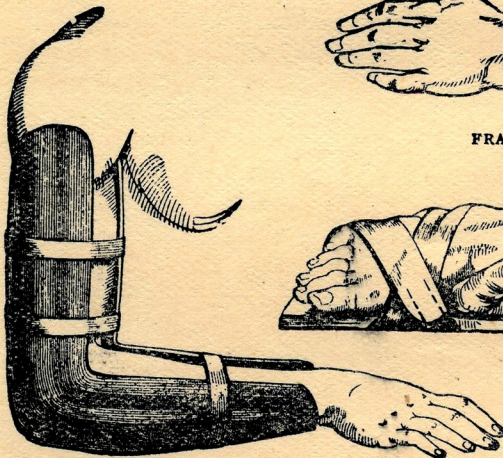
FRACTURE OF THE ARM.



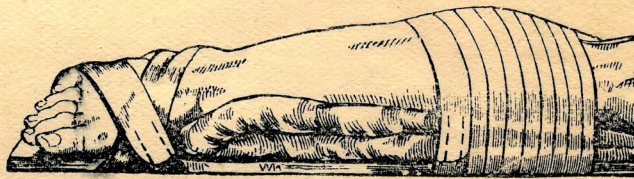
FRACTURE ON THE LOWER END OF THE RADIUS.



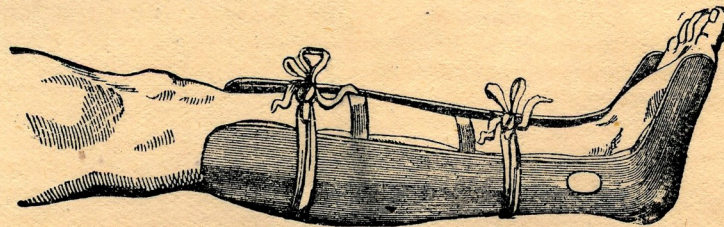
FRACTURE OF THE HUMERUS.



FRACTURE OF THE HUMERUS.



POTT'S FRACTURE.



FORM OF SPLINT USED IN THE TREATMENT OF FRACTURE OF BONES IN THE LEG.